

Transconjunctival Blepharoplasty with Simultaneous Lower Lid Skin Peel

JULIUS NEWMAN, MD, KIRK BRANDOW, MD, FREDERICK PETMECKY, MD

ABSTRACT: In the best of hands, resection of lower lid skin and/or muscle carries an unacceptably high incidence of lower lid malposition. Recognition of this fact has led to utilization of the transconjunctival approach as the preferred method of lower lid blepharoplasty. Combining this approach with a simultaneous skin peel obviates the need for transcutaneous or myocutaneous approaches in all but rare, selected cases. Even with severe skin laxity or in the presence of mild festoons, we choose to do a transconjunctival approach followed by a transcutaneous skin flap with a lateral pull.

Key Words: Transconjunctival blepharoplasty, Peel, Rhytids, Festoons

INTRODUCTION

Most patients requesting lower lid blepharoplasty present with a fullness in their lower lids, giving them the appearance of being tired and sad. This fullness represents excess fat bulging against a weakened orbital septum and may or may not be associated with skin rhytids.

Resection of the herniating lower lid fat has been shown to change the total surface area of the lower lid skin very little because one converts a convex deformity to a concave deformity. It has been our experience, in all but a few cases, that the necessity to resect skin can be avoided if one performs a transconjunctival blepharoplasty along with a simultaneous chemical peel that is tailored to the patient's severity of rhytids and skin type. Peel solutions such as 20, 25, 30, and 35% TCA; 88% Phenol and Litton's; or Baker's formula can be safely used when the retroseptal transconjunctival approach is utilized.

During the past three years, we have performed the transconjunctival approach, with and without chemical peels, in 95% of all patients presenting for blepharoplasty. We have essentially abandoned the transcutaneous approach in all but the most severe cases of lower lid rhytids and/or festoons. In such cases, we have performed a transconjunctival approach and then followed this with a

transcutaneous skin resection with a lateral pull. By avoiding incisions in the orbital septum, which is felt to be partially responsible for retraction of the lower lid,¹⁻³ we have had more consistent results devoid of complications.

HISTORICAL

The first known report of "unsightly hanging eyelid skin" was by Celsus in the first century A.D. Following this, sporadic reports of excision of excess eyelid skin have been found in earlier chronicle; however, it was not until 1818 that the term "blepharoplasty" was coined by Von Graffe and finally, in 1896, Fuchs coined the term "blepharochalasia." Early attempts to remove fat and skin from the lower lid were described by Kolle (1911), Noel (1924), Hart (1926) and Battman (1928). Interestingly, in 1908 and 1924, Miller reported what he thought were 13 different deformities that he treated with 13 separate lower eyelid incisions.⁴

Such surgeries no doubt led to significant scarring, so in the 1920s, a French surgeon, Bourguett, (1923 and 1928)⁵ reported his use of a novel transconjunctival approach to remove fat from the lower lid, thus avoiding the necessity to create an external incision. Two other French surgeons, Passot (1931) and Cloure (1931), also used this approach but interest was lost until Tessier (1955)⁶ utilized a transconjunctival approach to gain access to the orbital floor for reconstruction of congenital facial deformities. He and others^{7,8} described this approach for fat removal as well, but they felt there were many limitations.

Correspondence and reprint requests to: Kirk Brandon, M.D., Department of Aesthetic and Restorative Surgery, Graduate Hospital, 1455 City Line Avenue, Wynnwood, PA 19096.

The transcutaneous and myocutaneous approaches enjoyed great popularity during the 1960s and 1970s, but as recognition of postoperative lower lid malposition became more apparent, alternative approaches were sought. In the 1970s, the transconjunctival approach was repopularized by Tomlinson,⁹ who advocated a "pre-septal approach," as well as Askin, Lynch, and others,¹⁰ but occasional reports of scarring in the orbital septum with lower lid malposition led Baylis (1983)¹¹ to develop the retro-septal approach, which completely avoided entrance into the orbital septum. This has now been the standard approach for transconjunctival blepharoplasty.

PATIENT EVALUATION

Herniating lower lid fat gives the patient a tired and sad appearance (see Fig. 124). This is often apparent at an early age and has a strong familial predisposition. Grandmothers, mothers, and daughters may have remarkably similar appearances and they often request surgery together. The patient is examined in the upright position and then asked to look up. This maneuver will accentuate the bulge of the lower lid and help the surgeon to predict the amount of fat to be removed from each of the three compartments. Frequently, the medial and the central pads are well defined on either side of Lockwood's ligament (the arcuate expansion of the inferior oblique fascia) as viewed in the upright position pre-operatively. Following the examination, standard facial and close-up photographs are taken with the patient sitting. However, particular note of the position of the lateral fat pad should be made as it seems to be the most variable.

We make the determination of which peel solutions will be used during the initial evaluation. Skin type, color, and degree of rhytids are taken into consideration when making this plan. For simplicity, we choose either 20, 25, 30, or 35% TCA for young, light-skinned patients with mild rhytids. For deep wrinkles, with or without redundant skin, it is necessary to use a phenol solution. Most commonly, we use the 88% phenol and occasionally stronger solutions of the Linton's or Baker's formulas.

Special consideration is paid to brown-eyed, dark-skinned patients, who may experience some lightening of the skin following a phenol peel. We use TCA as the acid of choice with these patients. In the presence of ectropion or sclera show, phenol peels are contra-indicated because they may accentuate pre-existing problems. Therefore, we only use 20, 25, or 35% TCA, along with a transconjunctival removal of fat pads with a concomitant lateral lid suspension.

TECHNIQUE

The operation may be performed under local or general anesthesia. Reassessment of the amount of fat to be removed from each compartment is once again made in the upright position immediately prior to surgery. The pre-operative photographs are placed in the operating room for

reference during the resection of fat from each of the three compartments.

The table is positioned 15° in reverse Trendelenburg to reduce local venous congestion. One must examine the pupils for pupillary dilation or asymmetry prior to injection of the anesthesia. This is important so that one will not be confused by the presence of post-operative pupillary dilation, which is often noted following the use of epinephrine in the anesthetic. Tetracaine ophthalmic drops are then instilled into each conjunctival sac and a #23 mm scleral shield is placed over the cornea (Fig. 1). We have found that larger shields are often too cumbersome and obstructive when making the incision or identifying the fat pads.

We begin by icing the anesthetic carpouls for 20 minutes before injection because we feel that this may decrease bleeding. Two percent xylocaine with epinephrine 1:100,000 is used to anesthetize the lower lid with a dental syringe and a 30-gauge needle (Fig. 2); 1.5 cc are instilled on each side through a single puncture in the conjunctiva aiming retro-septally and just below the infraorbital rim. Only one pass is made in an effort to avoid multiple sticks in the conjunctiva and to avoid hematoma formation, which may occur if the needle is moved around while in the fat pads. Following this, we apply ice chips directly over the lower lid area for 5-10 minutes before making the incision.

A Teflon-coated Demares retractor is placed on the lid, and attention must be paid to the manner in which retraction is performed in order to avoid trapping the fat

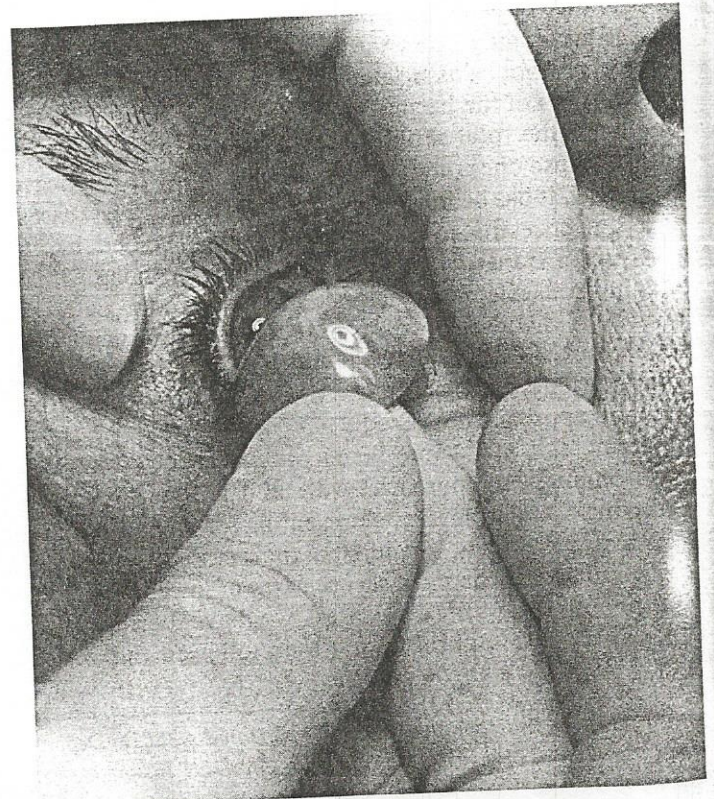


Figure 1. Insertion of 23 mm scleral shield to protect the cornea.

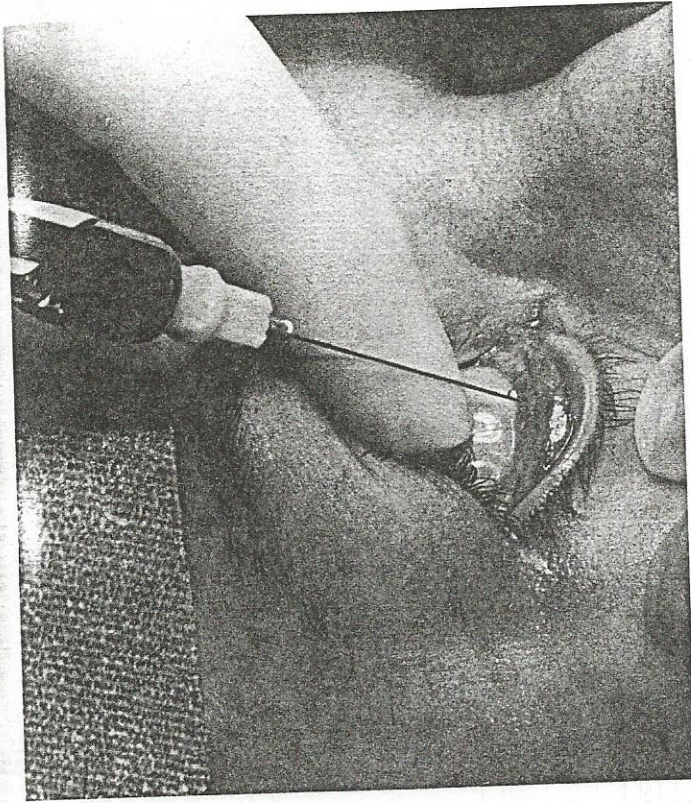


Figure 2. Transconjunctival lower lid infiltration using a dental syringe with a 30 g needle aimed toward infraorbital rim. 1.5 cc of 2% xylocaine with epinephrine 1:100,000 is instilled through a single stab wound.

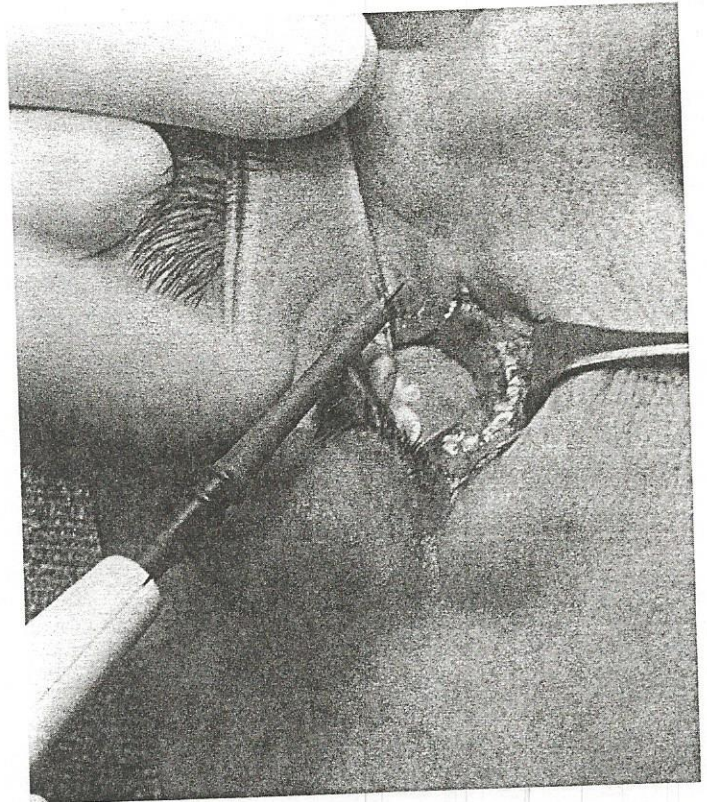


Figure 4. Number 8 red rubber catheter protects unipolar cautery from damaging surrounding skin.

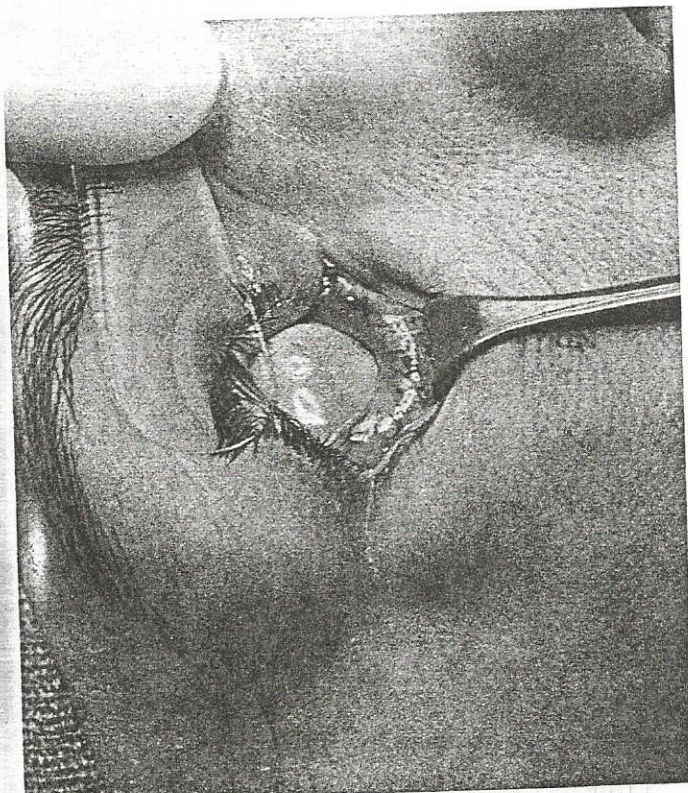


Figure 3. Plastic yaegar plate places pressure on globe while Teflon coated Demares retractor exposes bulging lower lid fat.

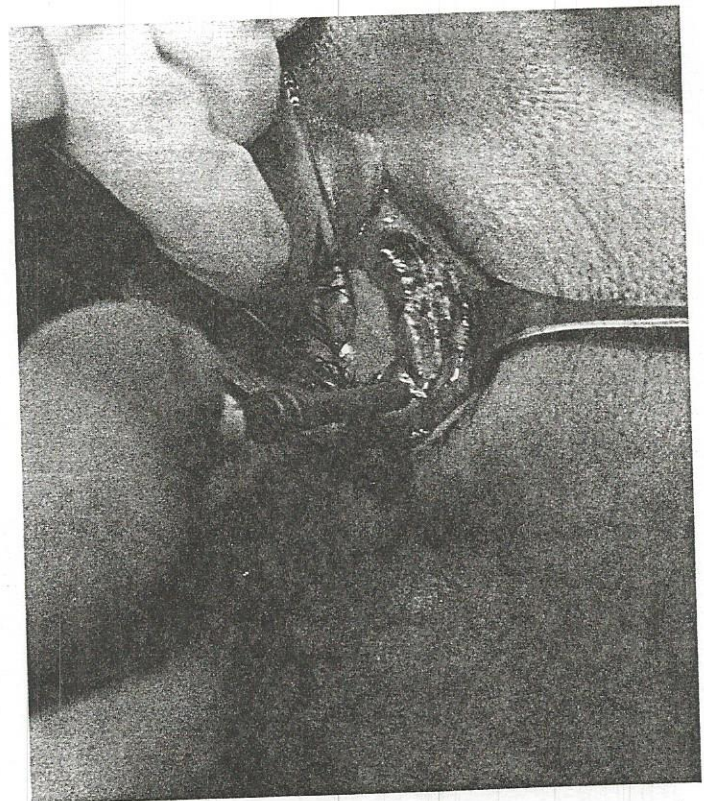


Figure 5. Transconjunctival incision made with unipolar, needle-tipped cautery.

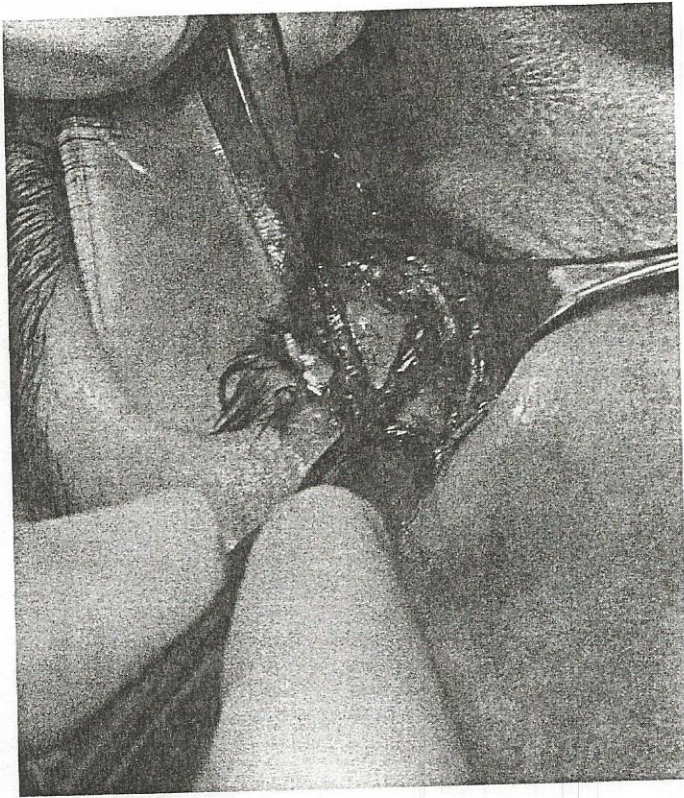


Figure 6. Lower forceps touching inferior oblique muscle which separates central from medial fat pads.

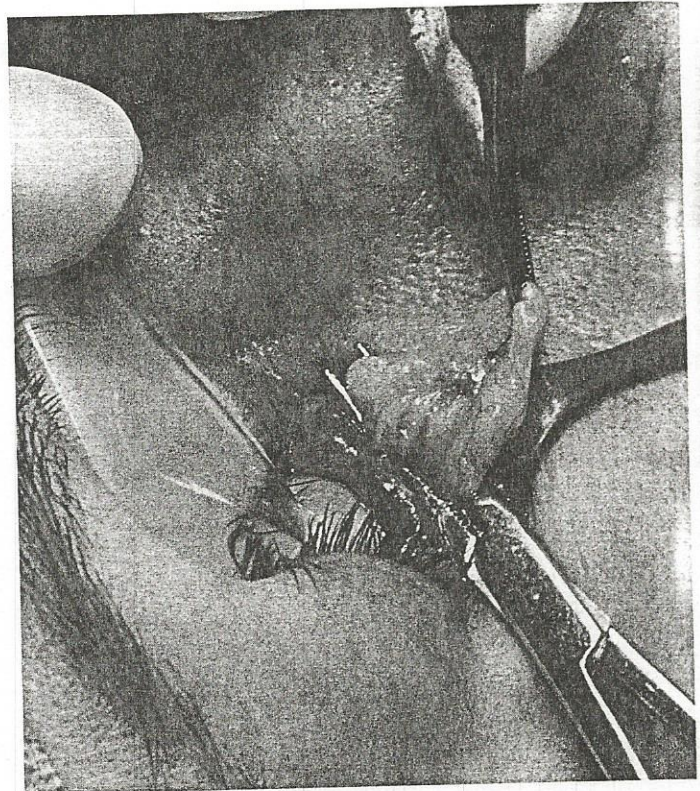


Figure 8. The central fat pad is clamped and then cauterized with a bipolar cautery.

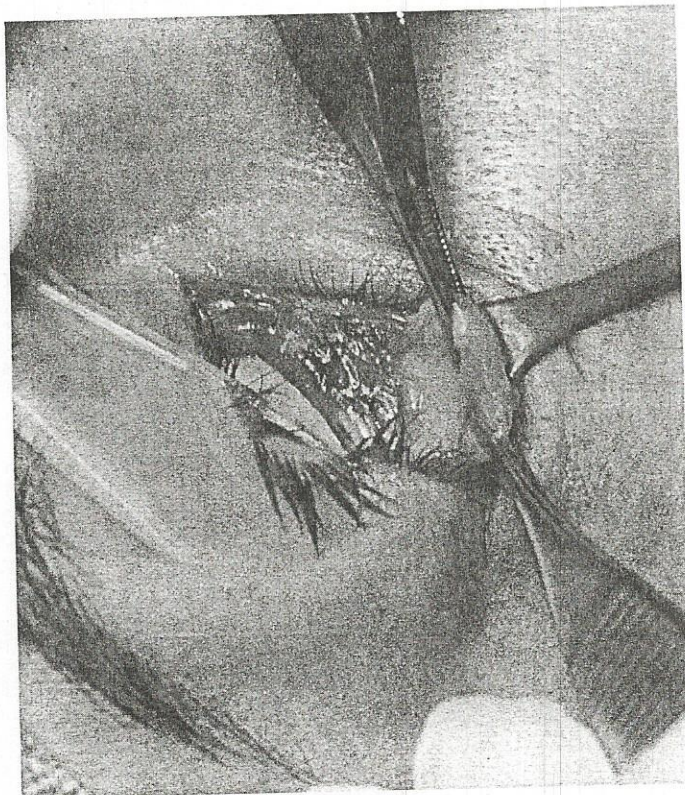


Figure 7. The "2-forceps technique" is used to tease out the central fat pad first.

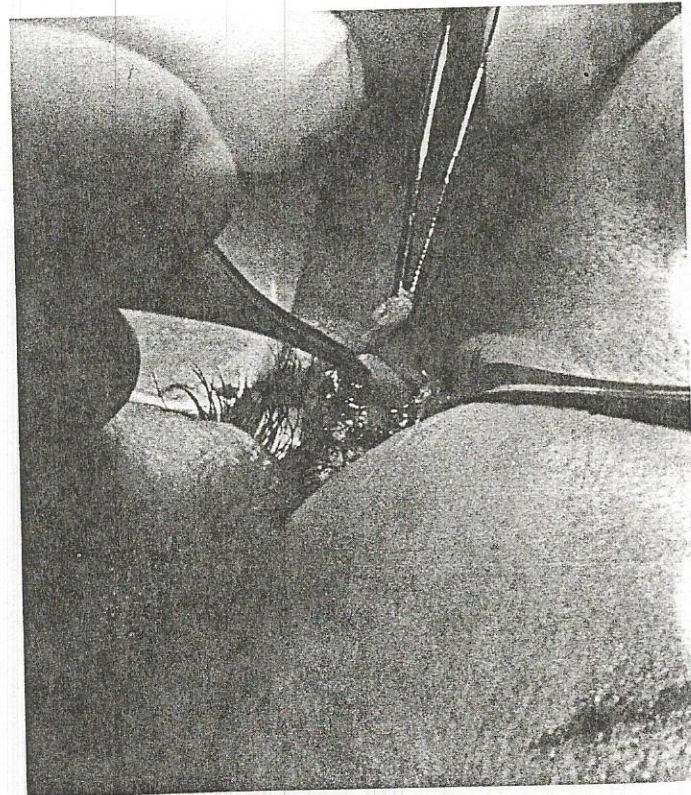


Figure 9. The lighter-colored, central fat pad is more easily identified once the central pad has been resected.

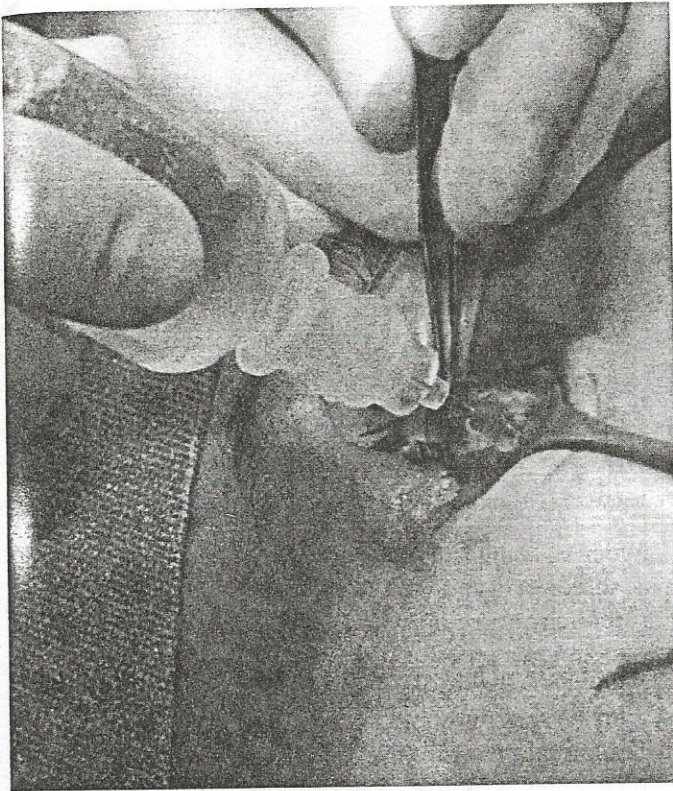


Figure 10. A saline wash is squirted into the wound to check for persistent bleeding.

pads behind the retractor. A plastic Jaeger plate is then placed over the eye shields and gentle pressure is applied on the globe to produce a herniation of the fat pads into the operative field. We prefer using the plastic Jaeger plate over the metal Jaeger plate, which could potentially conduct an electrical current and injure the cornea if it were inadvertently touched with the unipolar cautery (Fig. 3).

A number 8 red rubber catheter is placed over a standard needle tip unipolar cautery to prevent burning the surrounding tissue, which may occur when working in such a tight space (Fig. 4). The unipolar is set at 25 cutting, 10 coagulation, and blend one. During surgery, one must pay attention to the patient's EKG to watch for a cardio-ocular reflex, resulting from pressure on the globe. Therefore, all patients should be monitored carefully during surgery. In the presence of bradycardia, immediate removal of pressure on the globe should result in conversion to normal sinus rhythm.

The incision starts medially, at least 6 mm below and lateral to the punctum, and proceeds at this level laterally (Fig. 5). It is important to use a small Adson forceps to retract the lateral canthus in order to expose sufficiently the lateral pad, which can be quite inconspicuous because of its location more superiorly and laterally. Following this, the superior edge of the incision is grasped with a smooth forceps and lifted upward. This allows the cutting bovie to dissect easily while improving exposure of the fat pads.

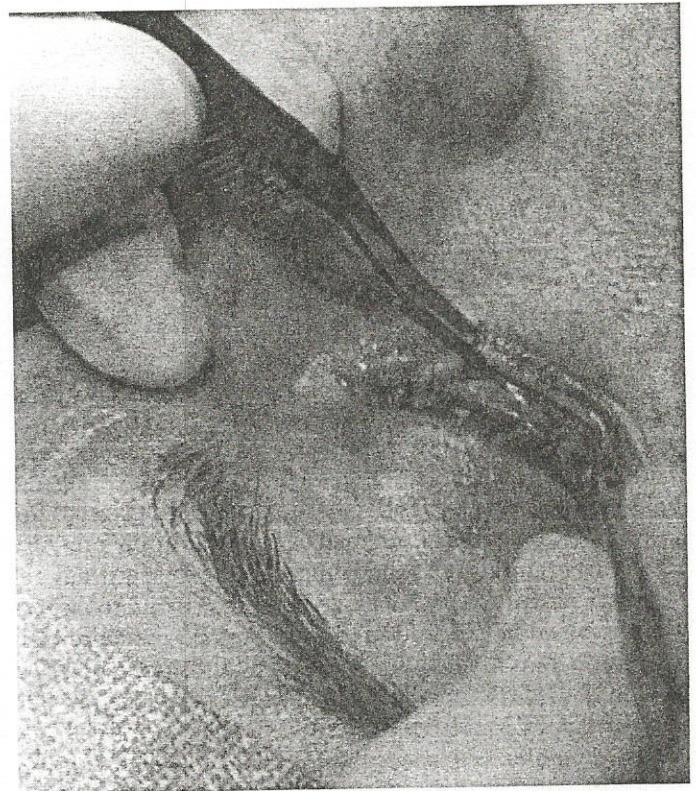


Figure 11. Conjunctiva is repositioned but no suturing is necessary to maintain the reapproximation.

Applying gentle pressure on the globe, the cautery splits the weak fascia to expose the inferior oblique muscle, which separates the medial fat pad from the central and lateral fat pads (Fig. 6). As the incision is deepened laterally, the arcuate expansion of the inferior oblique muscle (Lockwood's ligament) will be encountered. This second landmark separates the central from the lateral fat pad, but it is more superficial and harder to recognize than the inferior oblique muscle.

Fat is resected from the central fat pad first because this compartment seems to be the most easily exposed. We use two smooth Adson forceps to tease out the fat (Fig. 7). As the fat is brought out, there may be fine vessels within the fat pad which should be cauterized with a bipolar prior to the extraction. The central pad is extracted as far as possible into the operative field, clamped, resected, and cauterized using a bipolar cautery (Fig. 8).

Next we approach the internal pad, which in contrast to the central pad, does not bulge easily. The assistant again applies gentle pressure on the globe using two small Adson forceps, the central pad is pushed laterally to expose the lighter-colored, thicker-textured portion of fat in the most medial aspect of the incision (Fig. 9). It is then clamped, resected, and cauterized.

In many cases, the lateral pad is easily missed unless one applies gentle pressure on the globe while the assistant retracts laterally and superiorly. Occasionally, portions of the lateral pad are resected, but other portions may be left

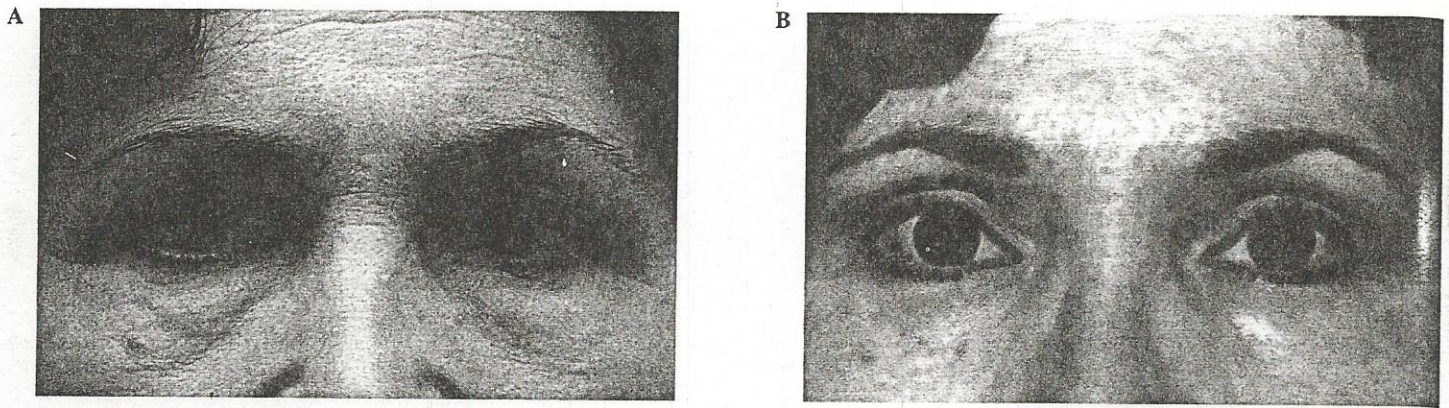


Figure 12. (A) Pre-op and (B) post-op. 47-year-old white female with trans bleph with 25% TCA Peel.

behind, because it occasionally seems to be loculated. So, after resection of the lateral pad, it is wise to apply pressure once again and inspect the compartment to see if any fat remains. A saline wash is squirted into the wound to inspect for any bleeding (Fig. 10) and the lower lid conjunctiva is then pulled up to allow for soft tissue reposition (Fig. 11). We do not feel that there is any need to suture the incision and have not done so for the last two years.

We then closely inspect the lower lid to identify if any persistent external bulges may still be present. The photographs are re-examined to be sure the resection matches the pre-operative clinical plan and then the eyeshields are removed and pupils rechecked. A combination antibiotic-steroid ointment is instilled into the inferior fornix at the very end. However, if we plan to do a concomitant peel, this is delayed until the peel is complete to avoid ointment oozing onto the lower lid skin.

For the past six months, we have instructed patients to place frozen, water-soaked camomile teabags on their eyes when they go home. This helps decrease edema and is quite comfortable. Before going home, all patients are examined for evidence of persistent pain or unilateral edema and then called the evening of surgery. They are seen the following day in the office and may begin using contacts 10 days post-operatively.

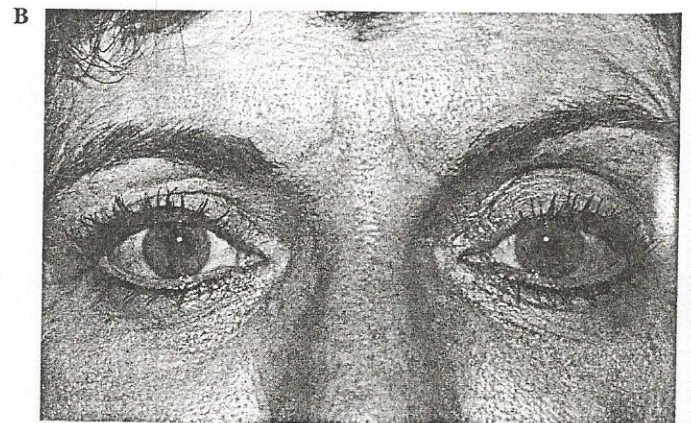
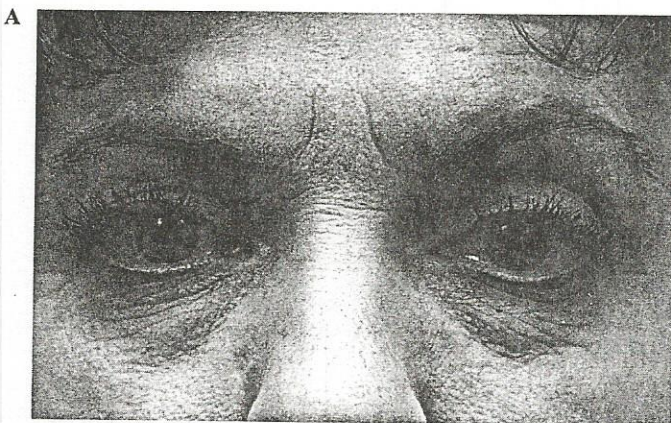


Figure 13. (A) Pre-op and (B) post-op. 50-year-old white female with trans bleph and 30% TCA Peel.

CHEMICAL PEELS

We have been using various chemical peel agents for the past three years and have found this to be a safe technique for treating lower lid rhytids and excessive skin. There are many surgeons performing transconjunctival blepharoplasty who will not perform simultaneous peels during surgery because they feel it is unsafe.

During the past three years of performing simultaneous peels, we have had no cases of postoperative ectropion; however, we have noted scleral show in 2 of 358 cases. Both of these cases involved patients who had previously undergone transcutaneous blepharoplasty and had retained fat pads necessitating a secondary procedure which we performed through the transconjunctival approach, followed with a phenol peel. Therefore, in cases of secondary blepharoplasty with evidence of lower lid laxity or poor snapback, phenol would not be the peel solution of choice, rather, a milder peel such as TCA 20–35%.

Scleral shields remain in place as extra protection to the eye during peeling. After the transconjunctival blepharoplasty has been completed, the head is then flexed to a 30° position in order to avoid retrograde spillage of the solution back into the eye. The lower lids are wiped with acetone on a cotton swab and then, using a fine tooth Adson forceps,

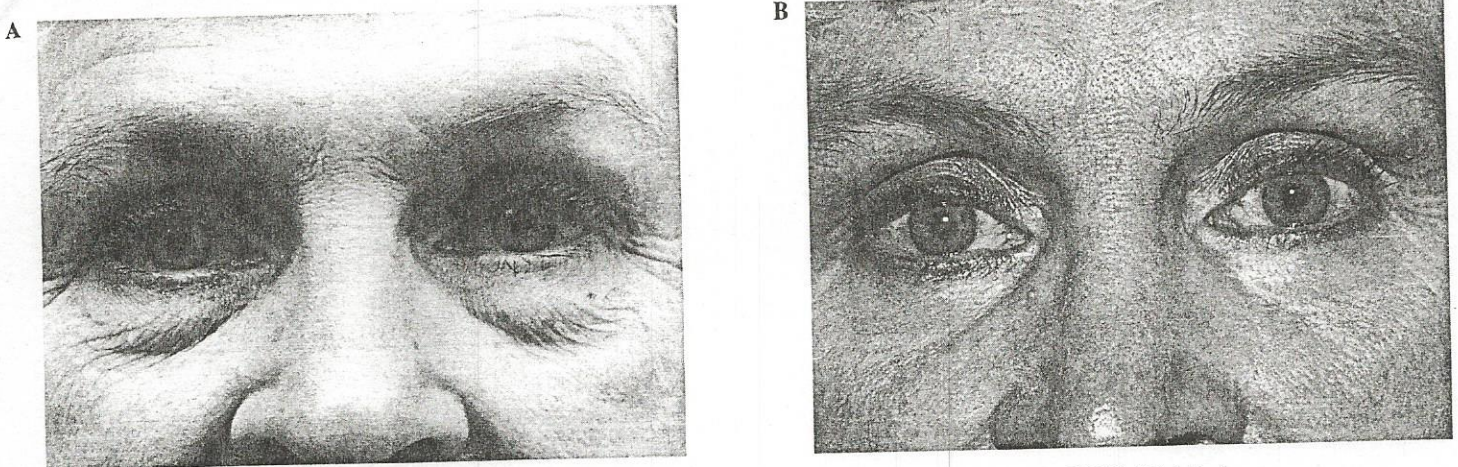


Figure 14. (A) Pre-op and (B) post-op. 62-year-old white female with trans bleph and 35% TCA Peel.

the lower lid is grasped at the ciliary margin and pulled upward. This accomplishes two things: it protects the eye against retrograde seepage and allows the wrinkled skin to become more taut so there are no skip areas between rhytids.

We use standard cotton tip applicators to apply the peel solution. By removing most of the cotton, leaving only a small wisp around the end of the wooden stick, we avoid dripping during application and make the application more accurate and safe. The stick is then placed in the peeling agent and a rolling action is started from the ciliary margin and continued downwards toward the infraorbital rim. We prefer this direction of application because it is more controlled. Utilizing a side to side motion increases the possibility of slipping and inadvertently placing peel solution too close to the medial or lateral canthus.

We often do extensive periorbital peels for wrinkles that extend below the lower lid area, as well as extending it up into the temporal area and over the lateral cheek to tighten up crow's feet. Some skin lightening may be seen with phenol when one leaves the natural periorbital, anatomic unit, but most patients will accept this as a fair trade-off to

be rid of the rhytids. Cover-up makeup can easily be used to cover these areas.

Topical antibiotic ointment is applied to the phenol peel as an occlusive dressing, but TCA will continue to penetrate if it is covered. Therefore, we leave TCA peels open for 4–6 hours following surgery and ask the patient to then dose water on their face. The following day, patients continue to apply antibiotic ointment over phenol peels. They do not place anything on the TCA peel until the fourth day, when they are instructed to take a shower and then apply Vaseline over the peel. Following this, they will notice the skin beginning to peel off within 4–6 hours.

During use of peels, one must be cautious about retrograde migration of phenol, through tears, back into the medial and lateral canthal areas. If phenol comes in contact with water, it will penetrate more deeply and could potentially cause a corneal injury if allowed to seep back into the eye. TCA will be neutralized by contact with water and if fluid mixes with TCA, it will weaken the penetration in that area, causing streaking in the peeled area.

Patients having TCA peels are advised that they will have dry, crinkled skin under the eye for the first four days, but

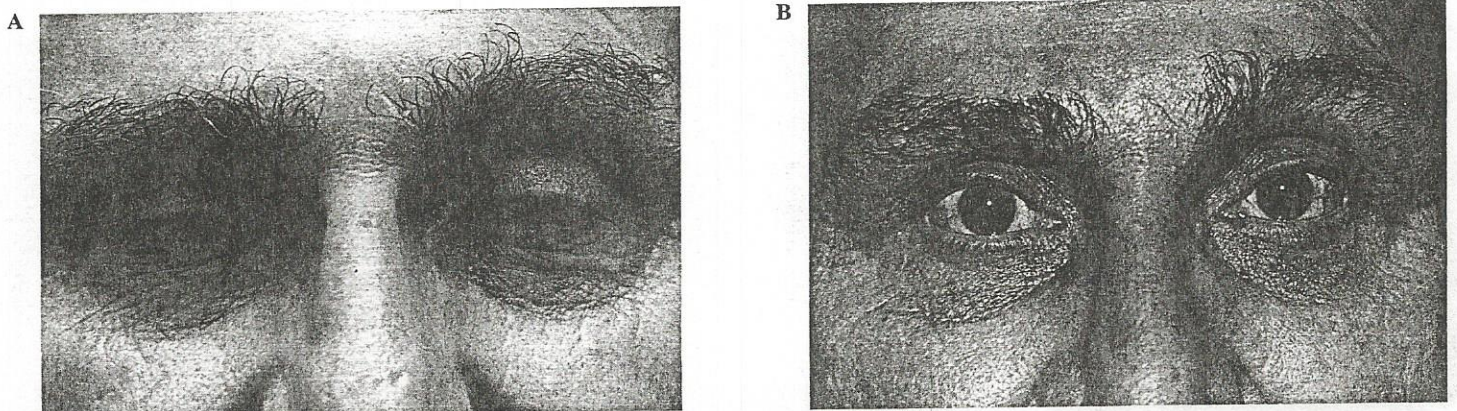


Figure 15. (A) Pre-op and (B) post-op. 64-year-old white male with trans bleph and 35% TCA Peel.

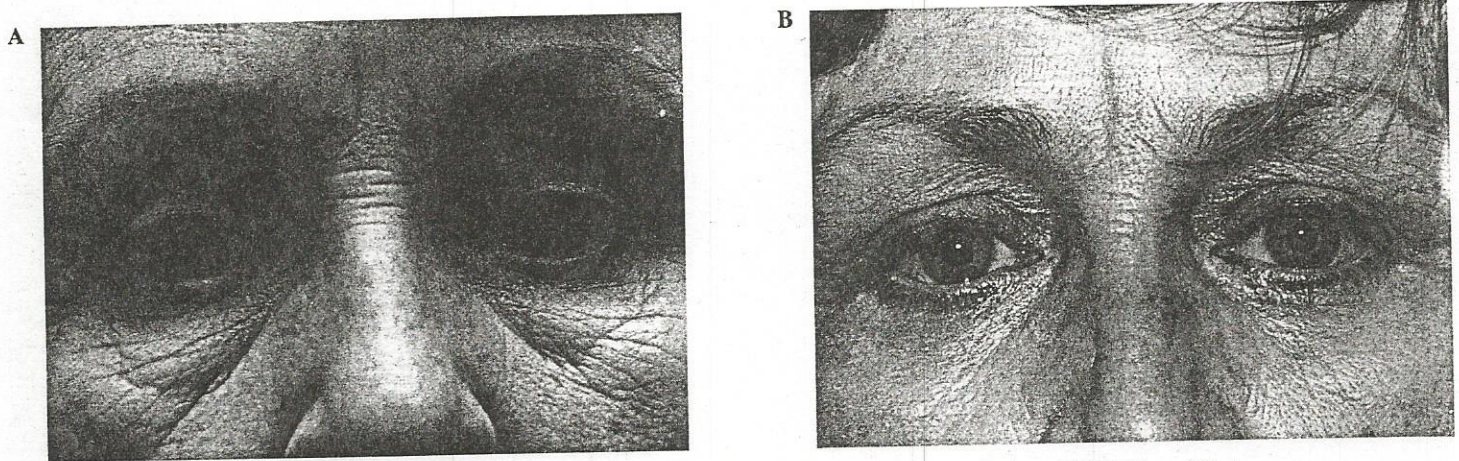


Figure 16. (A) Pre-op and (B) post-op. 53-year-old white female with trans bleph and 88% Phenol Peel.

will peel about the fifth day. Skin color usually returns within 10–14 days and they are advised to avoid makeup until the 14th day. Phenol, on the other hand, produces persistent erythema which may last up to 3–6 months; however, patients are allowed to use makeup on the second week, provided it is hypo-allergenic and fragrance free. Occasionally, we have used a mild steroid to decrease the hyperemia, which can be applied in an ointment form on the lower lid, beginning on the second or third week after a phenol peel. The patient is advised that there is some lightening of the skin using phenol, but in most cases it is difficult to notice, except in patients with dark skin and dark eyes.

DISCUSSION

Malposition of the lower lid is reported as the most common complication following transcutaneous blepharoplasty.^{12,13} While serious sequelae such as frank ectropion are rare, minor deformities such as lateral “bowing” or “scleral show” have been reported in some series in as much as 25% of patients.¹⁴ The etiology of lower lid malposition following transcutaneous lower lid blepharoplasty is not entirely clear, but violation of the orbital

septum with subsequent sclerosis is felt to be a major contributing factor by Baylis. Some believe it is the removal of lower lid skin which decreases vertical lid height, and causes the lower lid to be pulled down,¹⁵ while others think that the medial pull exerted by the shortened orbicularis causes rounding at the lid margin and ultimately results in a “bow string” effect. Surprisingly, though, some degree of lateral bowing probably goes unobserved as a very frequent postoperative occurrence because patients are reportedly pleased by their more “wide-eyed” appearance.

In procedures that do not require skin resection, but where herniating fat pads are present, it has been reported that the fat pads can be accessed directly through an orbital septal stab wound with electrodesiccation of the fat pads. Others have performed a herniorrhaphy of the orbital septum without even removing orbital fat in order to push fat pads back into the globe. Even in these cases, lower lid malposition has been reported and is felt to be due to scarring of the orbital septum.^{16,17}

Patients in their late 60s and older are at increased risk for postoperative complications with transcutaneous or

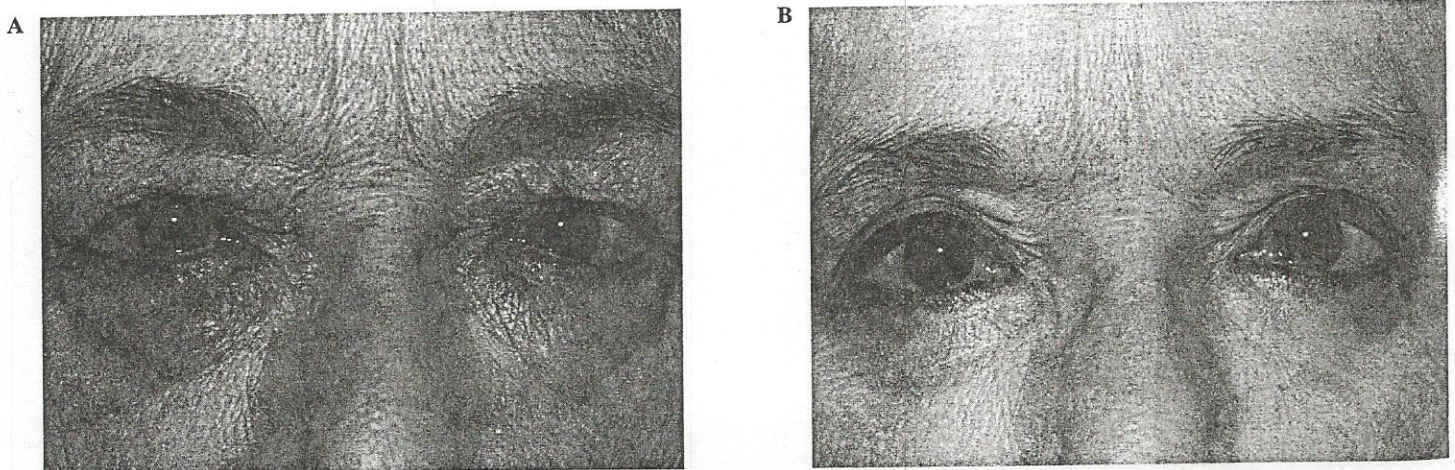


Figure 17. (A) Pre-op and (B) post-op. 70-year-old white female with trans bleph and Litton's Formula.

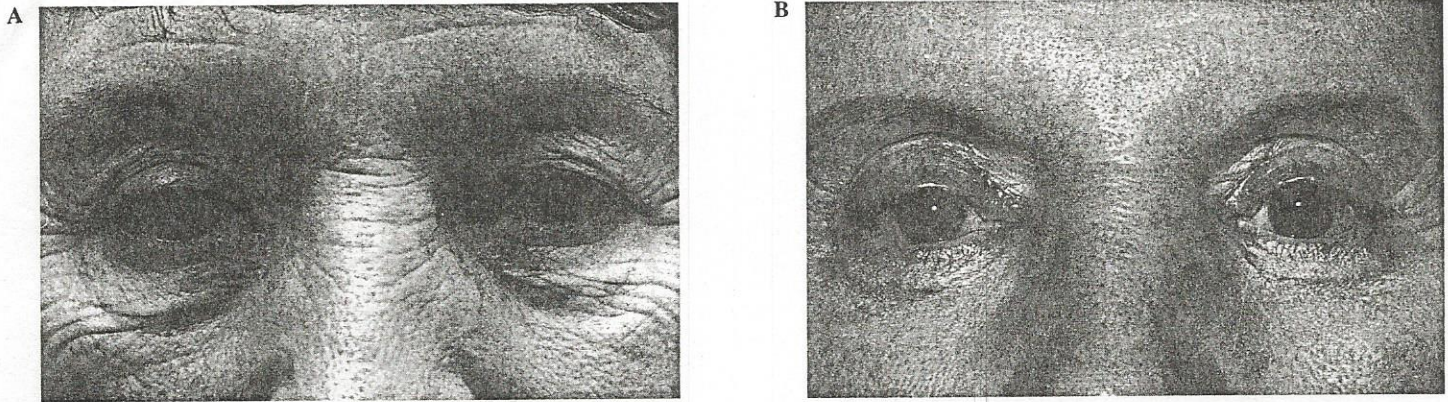


Figure 18. (A) Pre-op and (B) post-op. 73-year-old white female with trans bleph and Baker's Formula.

myocutaneous blepharoplasty because of loss of skin elasticity, as well as varying degrees of atrophy of the tarsal plate. Potential for postoperative malposition in these patients appears more likely. Additionally, patients with excessive skin redundancy and malar bags (festoons), are often treated with excessive resection of lower lid skin and/or muscle, which may lead to ectropion.

Consequently, multiple procedures have been advocated to avoid and treat the sequelae of transcutaneous and myocutaneous blepharoplasty. Such techniques include lid shortening, lateral canthal plication or canthopexy,^{18,19} orbicularis muscle suspension,²⁰ canthal suspensions with pre-tarsal orbicularis muscle "slings," tarsal tuck, and tarsal strip suspensions.^{21,22}

In an attempt to avoid postoperative lower lid malposition, we have developed a program utilizing transconjunctival blepharoplasty with a simultaneous chemical peel. Utilizing this concept, we have found that approximately 30% of patients are served well by strictly performing transconjunctival fat resection alone. The other 70%, in our practice, had combined fat resection and simultaneous skin peels. The agents which we use most commonly for concomitant chemical peels are 20, 25, 30, and 35% TCA, 88% phenol, and Litton's and Baker's formulas.

On occasion, where excessive skin laxity and festooning are present, we perform a transconjunctival blepharoplasty in conjunction with a transcutaneous skin resection where the vector of the pull is lateral and sutures are tacked down to the periosteum for support. In such cases, we do not use peels because of the risk of necrosis of the cutaneous flap.

CONCLUSION

During the past three years, we have been performing the combined transconjunctival lower lid blepharoplasty with and without chemical peels and have been quite pleased with our results while avoiding many of the problems seen with the transcutaneous and myocutaneous approaches. Because this procedure can be performed more rapidly, operating room and anesthesia times have decreased. Patients can return to work within 4-5 days with minimal ecchymosis, making them appear as if nothing had been done. With the use of simultaneous chemical peels, we have been able to produce excellent results with very high patient satisfaction.

It is our personal opinion that there is rarely any need to perform blepharoplasty through the transcutaneous or myocutaneous incisions. Over the past three years, we have

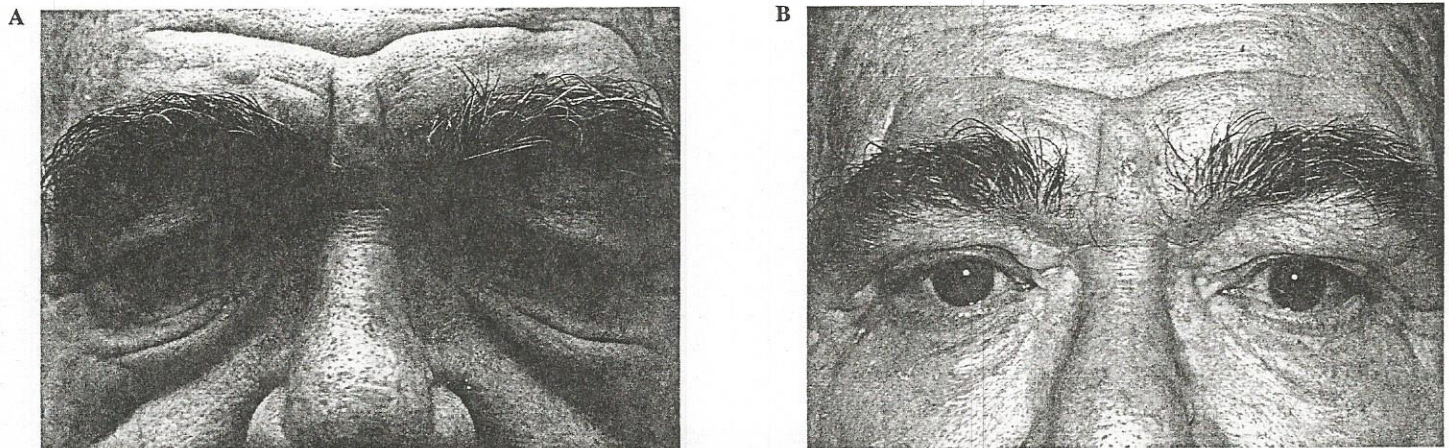


Figure 19. (A) Pre-op and (B) post-op. 76-year-old white male with trans bleph and transcutaneous skin lift.

performed 383 transconjunctival blepharoplasty procedures, during which 70% underwent a simultaneous chemical peel. We have had no cases of ectropion or scleral show with or without simultaneous peels when the surgery was performed as a primary approach. However, we have noted two scleral shows in secondary transconjunctival blepharoplasty performed with a simultaneous phenol peel in a patient who had previously undergone a transcutaneous blepharoplasty. Because of this, we have discontinued using phenol agents for patients with secondary blepharoplasty.

REFERENCES

1. McCollough EG, English JL: Blepharoplasty. Arch Otolaryngol Head Neck Surg 1988; 114:645-648.
2. Loeb R: Scleral show. 1988; Aes Pl Surg 12:165-170.
3. Adams BJS, Feurstein SS: Complications of blepharoplasty. Ear, Nose, Throat Journal 1986; 65:6-11.
4. DePuig C, Rees T: Historical notes on blepharoplasty. Plast Reconstr Surg 47(3):246-251.
5. Bourget I: La Correction esthetique des diverses deformation nasales. Rev Int de Laryngologic 1926; Oct:133-137.
6. Katzen LB: The history of cosmetic blepharoplasty. Adv Ophthal Plast Reconstruct Surg 1986; 5:89-96.
7. Constanares S: Blepharoplasty for herniated intraorbital fat. Plas Reconstr Surg 1951; 8:46-58.
8. Converse JM, Firmin F, Wood-Smith D, et al: The conjunctival approach in orbital fractures. Plast Reconstr Surg 1973; 52(6):656-661.
9. Tomlison FB, Hovey LM: Transconjunctival approach in lower lid blepharoplasty for removal of fat. Plast Reconstr Surg 1975; 56:314-318.
10. Lynch DJ, Lamp JL, Royster HP: The conjunctival approach for exploration of the orbital floor. Plast Reconstr Surg 1974; 54(2):154-156.
11. Baylis HI, Sutcliffe RT: Conjunctival approach in lower eyelid blepharoplasty. Adv Ophthal Plast Reconstruct Surg 1983; 2:43-54.
12. McGraw BL, Adamson PA: Postblepharoplasty ectropion prevention & management. Arch Otolaryngol Head Neck Surg 1991; 177.
13. McCord CD, Shore JW: Avoidance of complications in lower lid blepharoplasty. Ophthalmology 1983; 90:1039-1046.
14. Carraway JH, Mellow CG: The prevention and treatment of lower lid ectropion following blepharoplasty. Plast Reconstr Surg 1190:971-981.
15. Reese TD: Prevention of ectropion by horizontal shortening of the lower lid during blepharoplasty. Ann Plast Surg 198; 11:17-23.
16. Bisaccia E, Scarbrough DA, Swensen RD: A technique for blepharoplasty without incising or "puncturing" orbital septum. Dermal Surg Oncol 1990; 16:4.
17. Sachs ME, Bosniak SL: Correction of true periorbital fat herniation in cosmetic lower lid blepharoplasty. Aesth Plast Surg 1986; 10:111-114.
18. Monasterio FO, Rodriguez A: Lateral canthoplasty to change the eye slant. Plast Reconstr Surg 1985; 75(1).
19. Whitaker LA: Selective alteration of palpebral fissure for by lateral canthopexy. Plast Reconstr Surg 1984; 74(5).
20. Webster RC, Davidson TM, Reardon EJ, Smith R: Suspending sutures in blepharoplasty. Arch Otolaryngol 197; 105.
21. Jordan DR, Anderson RL: The tarsal tuck procedure. Avoiding eyelid retraction after lower blepharoplasty. Plast Reconstr Surg 1990; 85(1).
22. Lisman RD, Rees T, Baker D, Smith B: Experience with tarsal suspension as a factor in lower lid blepharoplasty. Plast Reconstr Surg 1987; 79(6).